



# Unicornuate Uterus with Non-Communicating Rudimentary Uterine Horn on MRI: A Case Report

Dr Quratulain Haroon \*, Dr Raisa Altaf, Dr Sadaf Nasir, Dr Awais

Department of Radiology, Liaquat National Hospital and Medical College Karachi, Pakistan.

\*Corresponding author: Dr Quratulain Haroon; [anizeeshan58@gmail.com](mailto:anizeeshan58@gmail.com)

Received 07 January 2025;

Accepted 13 February 2025;

Published 22 February 2025

## Abstract

Uterine anomalies resulting from abnormal embryologic development of the Mullerian ducts are often detected incidentally on imaging for other indications. This case report presents the finding of a non-communicating rudimentary uterine horn on MRI in a 31-year-old married female, along with a discussion of the typical imaging features, clinical implications, and management considerations for this rare anomaly. This report highlights the crucial role of imaging in diagnosing Mullerian duct abnormalities.

**Keywords:** *Mullerian duct anomalies, unicornuate uterus, rudimentary uterine horn, MRI, conservative management.*

## Introduction

Uterine anomalies are estimated to occur in ~4% of women, resulting from disrupted embryological development of the paramesonephric (Mullerian) ducts during organogenesis [1]. These developmental disorders of the female reproductive tract include septate, bicornuate, arcuate, and unicornuate uteri. Unicornuate uterus, representing ~10% of Mullerian anomalies, results from complete or partial non-development of one Mullerian duct [2]. This can be associated with a rudimentary uterine horn on the affected side.

The rudimentary horn is typically non-communicating and lacks connectivity to the contralateral uterine cavity [3]. Though it is the rarest congenital anatomic anomaly of the female genital system, causing many obstetrical and gynecologic complications [1,3]. Important clinical implications include increased risks of reproductive problems such as infertility, miscarriage, preterm birth, and ectopic pregnancy [4]. Most significantly, pregnancies in the rudimentary horn carry life-threatening risks of rupture and severe hemorrhage during the second or third trimester [5]. Therefore, early diagnosis is critical but challenging as most cases are detected incidentally. Imaging plays a vital role in diagnosing Mullerian duct anomalies to guide management. We present a case of a non-communicating rudimentary uterine horn

It results from complete or partial failure of the development of one of the Müllerian ducts [1,4]. Concomitant urinary tract abnormalities have been reported in up to 40% of cases, of which the most common is unilateral renal agenesis [5]. The prevalence of a unicornuate uterus is reported to be higher in women with a history of infertility and recurrent miscarriage [4,6]. However, the real impact of this anomaly on reproductive outcome is still unclear as, historically, it was diagnosed only in highly selective patient groups,

such as women presenting with infertility, pelvic pain or rudimentary-horn pregnancy [7,8].

## Case Presentation

A 31-year-old married female with history of preterm delivery 5 years back now presented with left lower abdominal pain for 3 months. Physical examination of the abdomen revealed mild abdominal tenderness of the left lower abdominal quadrant. no menstrual irregularities was observed. Previous ultrasound abdomen and pelvis done outside our hospital showed absent left kidney, two uterine cavities, and left adnexal cystic structure with internal septations measuring 3.0\*3.2 cm, which were initially reported as HYRLIN WERNER WUNDERLICH SYNDROME (didelphys uterus, obstructed hemivagina, ipsilateral renal agenesis). To better evaluate the findings and by keeping in mind, the frequent association of congenital anomalies of the reproductive system with renal anomalies, an MRI was recommended and performed. MRI pelvis showed a curved contour of uterus with normal zonal anatomy and deviation towards right side. Normal looking cervix and vagina. A rudimentary non communicating uterine horn is seen on left side with dilated endometrium filled with high signal intensity fluid within it suggestive of haematometra. A fibrous tract is seen extending from it to right uterine cornua. all these findings represent right unicornuate uterus with rudimentary non communicating left sided horn. A tortuous dilated tubular fluid filled structure is seen in left adnexa, showing fluid levels appearing high signals on T1 and T2WI representing left sided haematosalpinx.

After extensive counseling, the patient opted for conservative management with analgesics and oral contraceptives for symptom relief. Excision of the rudimentary horn was offered for definitive treatment, but the patient declined surgery at the time of diagnosis.

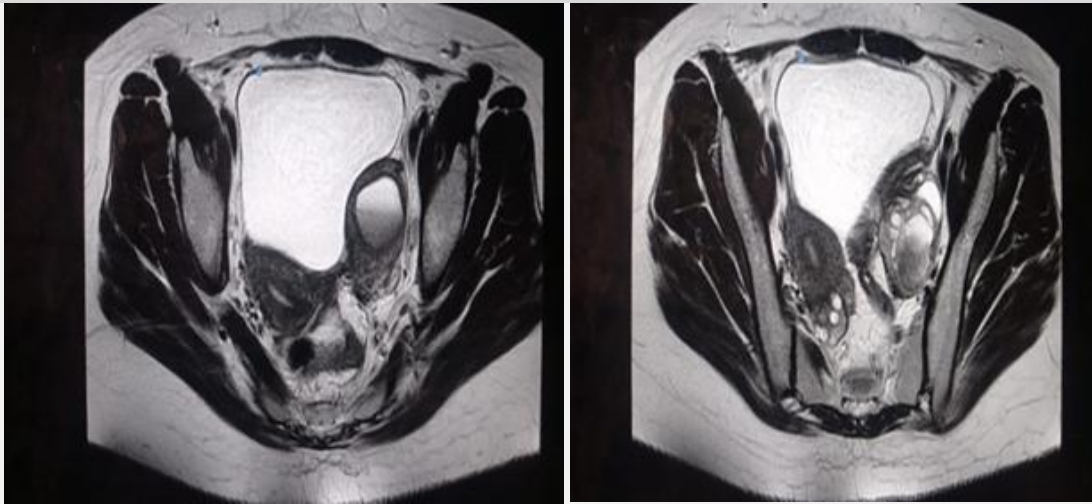


Figure 1: MRI of the pelvis. (A) right horn with normal zonal anatomy and left haematometra. (B) The normal right uterine horn, and, mild left hematosalpinx

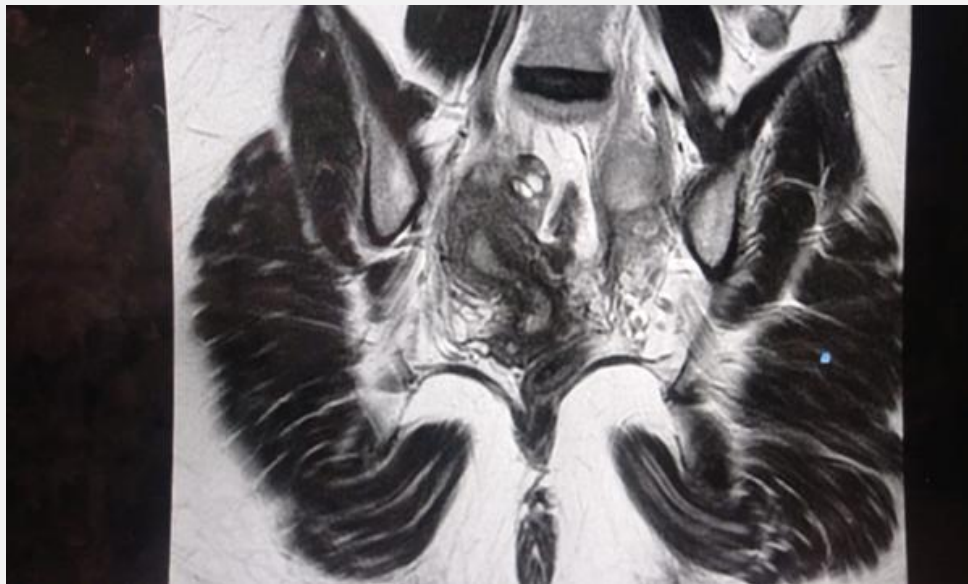

Figure 2: Coronal image of MRI pelvis showing right-sided uterine horn

## Discussion

This case highlights the utility of MRI in detecting Mullerian duct anomalies. MRI delineates the internal and external uterine architecture [6]. Typical MRI findings suggestive of a non-communicating rudimentary horn include the presence of myometrium surrounding the endometrium on both sides, giving a "two cavity" uterine appearance, Uterine duplication with displacement of the central fundal cleft to one side, Absence of communication between the two uterine horns, A thick muscle segment seen extending laterally from the main uterus, Unilateral renal agenesis on the same side as the anomaly in ~40% of cases [7].

Non-communicating rudimentary uterine horns are typically asymptomatic, but important clinical implications include increased risks of reproductive problems such as infertility, miscarriage, and ectopic pregnancy [4]. Most significantly, pregnancies in the rudimentary horn carry life-threatening risks of rupture and severe hemorrhage during the second or third trimester [5]. Therefore, early diagnosis is critical but challenging as most cases are detected incidentally. The detection of this anomaly has vital implications for patient management and counseling. MRI provides definitive diagnosis and helps exclude differential diagnoses like bicornuate uterus, adenomyosis, leiomyomas, and pregnancy in the cornua [8].

3D ultrasound also shows promise in diagnosing uterine anomalies but is operator-dependent [9]. Hysteroscopy and laparoscopy remain the gold standard but are invasive [10].

Optimal management remains debated since many patients are asymptomatic. However, risks associated with non-communicating rudimentary horns like ectopic pregnancy, infertility, and hemorrhage may warrant surgical resection [11]. Modern approaches emphasize fertility-preserving laparoscopic techniques [12]. Leaving the anomaly untreated runs the risks of life-threatening rupture during pregnancy. Careful patient selection and counseling are needed regarding timing of surgery and weighing risks/benefits of excision versus conservative management with close monitoring [13,14].

## Conclusion

Non-communicating rudimentary uterine horns are rare Mullerian anomalies, often detected incidentally on imaging. Early diagnosis through MRI is essential to guide appropriate management and mitigate potential complications whilst preserving fertility. The risk of rupture during pregnancy makes careful patient selection and counseling regarding timing of surgery or conservative management

crucial. A multidisciplinary approach weighing risks and benefits of resection versus conservative treatment optimizes patient care.

## Declarations

## Ethics approval and consent to participate

Taken from the patient.

## Informed consent statement

Obtained and a copy of the written consent is available on the corresponding author.

## Conflicts of Interest

The authors declare that there is no conflict of interest.

## Funding Statement

None

## References

- [1] Chan YY, Jayaprakasan K, Zamora J, Thornton JG, Raine-Fenning N, Coomarasamy A. The prevalence of congenital uterine anomalies in unselected and high-risk populations: a systematic review. *Hum Reprod Update*. 2011;17(6):761-771.
- [2] Nahum GG. Rudimentary uterine horn pregnancy part II: modern management and future prospects. *Early Pregnancy*. 2000;4(4):225-238.
- [3] Nahum GG. Rudimentary uterine horn pregnancy. The twentieth-century worldwide experience of 588 cases. *J Reprod Med*. 2002;47(2):151-163.
- [4] Fedele L, Bianchi S, Tozzi L, Vignali M. A new laparoscopic treatment for rudimentary horn pregnancy. *Fertil Steril*. 1996;66(5):964-966.
- [5] Chan YY, Jayaprakasan K, Zamora J, Thornton JG, Raine-Fenning N, Coomarasamy A. The prevalence of congenital uterine anomalies in unselected and high-risk populations: a systematic review. *Hum Reprod Update*. 2011;17(6):761-771.
- [6] Heinonen PK. Unicornuate uterus and rudimentary horn. *Fertil Steril*. 1997;68(2):224-230.
- [7] Jayasinghe Y, Rane A, Stalewski H, Grover S. The presentation and early diagnosis of the rudimentary uterine horn. *Obstet Gynecol*. 2005;105(6):1456-1467.
- [8] Fedele L, Bianchi S, Tozzi L, Vignali M. A new laparoscopic treatment for rudimentary horn pregnancy. *Fertil Steril*. 1996;66(5):964-966.
- [9] Raga F, Bauset C, Remohi J, Bonilla-Musoles F, Simon C, Pellicer A. Reproductive impact of congenital Mullerian anomalies. *Hum Reprod*. 1997;12(10):2277-2281.
- [10] Fedele L, Dorta M, Brioschi D, Massari C, Candiani GB. Magnetic resonance evaluation of double uteri. *Obstet Gynecol*. 1989;74(5):844-847.
- [11] Troiano RN, McCarthy SM. Mullerian duct anomalies: imaging and clinical issues. *Radiology*. 2004;233(1):19-34.
- [12] Nahum GG. Rudimentary uterine horn pregnancy. The twentieth-century worldwide experience of 588 cases. *J Reprod Med*. 2002;47(2):151-163.
- [13] Heinonen PK. Unicornuate uterus and rudimentary horn. *Fertil Steril*. 1997;68(2):224-230.
- [14] Atmaca R, Germen AT, Burak F, Kafkasli A. Acute abdomen in a case with noncommunicating rudimentary horn and unicornuate uterus. *JSL: Journal of the Society of Laparoendoscopic Surgeons*. 2005 Apr;9(2):235.



**Open Access** This article is licensed under a Creative Commons Attribution 4.0 International License, which permits use, sharing, adaptation, distribution and reproduction in any medium or format, as long as you give appropriate credit to the original author(s) and the source, provide a link to the Creative Commons license, and indicate if changes were made. The images or other third-party material in this article are included in the article's Creative Commons license, unless indicated otherwise in a credit line to the material. If material is not included in the article's Creative Commons license and your intended use is not permitted by statutory regulation or exceeds the permitted use, you will need to obtain permission directly from the copyright holder. To view a copy of this license, visit <https://creativecommons.org/licenses/by/4.0/>.

© The Author(s) 2025