

Indian Dermoscopic Study of Forty Six Cases of Lichen Planus Pigmentosus - New Dermoscopy Signs Discovered

Rahul Kumar Sharma*, Rajendra Kumar Sharma

RK Skin and Endocrine Center Panchsheel C Block C-929 Ajmer Rajasthan



Abstract:

*Lichen planus pigmentosus (LPP) is a atypical pigmented variety of lichen planus. Lichen planus pigmentosus is an unpredictable relapsing idiopathic dermatosis with periods of activation and remission with poor response to treatment and may leads to cosmetically disfiguring post inflammatory pigmentation. **Aim** - To study dermoscopic features of untreated cases of Lichen planus pigmentosus. **Study subjects** - All the patients who attended the dermatology clinic from November 2015 to November 2017 with the clinical diagnosis of LPP and who fulfilled the inclusion and exclusion criteria. **Methodology** - All the patients who attended the dermatology clinic with the diagnosis of LPP were examined by a dermatoscope. Dermoscopy was performed with DLA dermatoscope. The images were further magnified with smart phone. **Results** - Our study showed various dermoscopic signs in cases of LPP like annular granular pattern (35 cases), annular globular pattern (5 cases), homogeneous brown pigmentation (12 cases), homogeneous brownish black pigmentation (8 cases), brownish ovoid nests (3 cases), bluish blackish fine dots (4 cases), Wickham's striae(2 cases) and pigmented targetoid globules(3 cases). **Discussion** - Dermatoscope is an indispensable valuable tool in clinical practice which helps in making early lucid diagnosis of LPP with very high accuracy. Our study showed that annular granular pattern is the commonest pattern in Indian LPP cases followed by homogeneous brown pigmentation. In our Indian LPP dermoscopy study we discovered three novel dermoscopic signs which includes brownish globular nests, pigmented targetoid globules and bluish blackish fine dots. In our study we got few unique cases where Wickham's striae was also present with other dermoscopic signs which supports the link of LPP to lichen planus. Dermoscopic diagnosis of LPP is made by combination of various signs and should not be dependent on the presence of single marker.*

Keywords: *Lichen planus pigmentosus, Dermoscopy of dark skin type, Dermoscopy of LPP, Dermatoscope*

Introduction

Lichen planus pigmentosus (LPP) is an atypical pigmented variety of lichen planus.^[1] It is diagnosed by the presence of irregularly-shaped brownish black to gray patches. The forehead, temples, neck and upper chest are most commonly affected as LPP has propensity for photo exposed areas.^[2,3] Furthermore, the patches of LPP can also involve trunk or flexures (i.e. the axilla, groin, etc).^[1-3] Lichen planus pigmentosus is an unpredictable relapsing dermatosis with periods of activation and remission with poor therapeutic response and may leads to cosmetically disfiguring post inflammatory pigmentation. The aetiopathogenesis of LPP is still a mystery, but previous publications have revealed that it may be triggered by light, viral infections, or cosmetic photo sensitizers applied to the skin.^[1-4] Treatment for LPP is very cumbersome and it is tailored according to the patient.^[3]

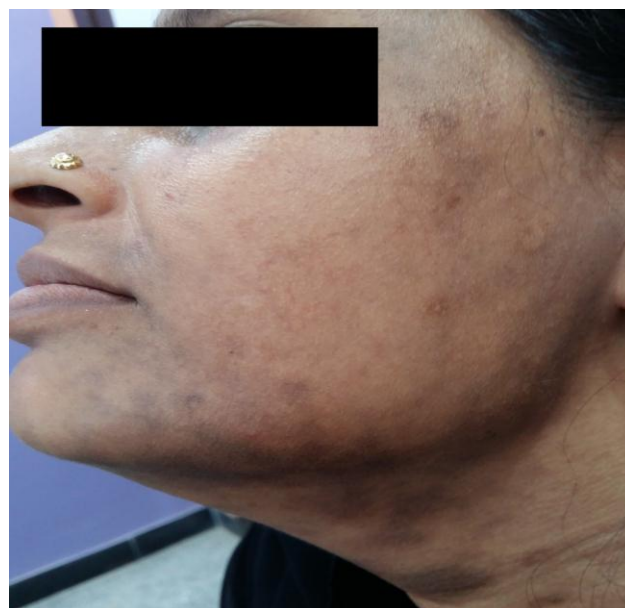

Figure 1: Clinical image of LPP lesions

Aim - To study dermoscopic features of untreated cases of Lichen planus pigmentosus

Study subjects - All the patients who attended the dermatology clinic from November 2015 to November 2017 with the clinical diagnosis of LPP and who fulfilled the inclusion and exclusion criteria.

Inclusion criteria

All biopsy proven cases of Lichen planus pigmentosus

Exclusion criteria

- 1) Inability to give consent
- 2) Where biopsy was inconclusive
- 3) Patients undergoing treatment for LPP

Study period - Two year (from November 2015 to November 2017).

Methodology

All the patients who attended the dermatology clinic from November 2015 to November 2017 with the diagnosis of LPP and who fulfilled the inclusion and exclusion criteria were recruited for the study. Dermoscopy was performed with DL4 dermatoscope. The images were further magnified with smart phone.

Results

We recruited 46 patients of biopsy proven LPP during two years study period. Our study showed various dermoscopic signs in cases of LPP like annular granular pattern (35 cases), annular globular pattern (5 cases), homogeneous brown pigmentation (12 cases), homogeneous brownish black pigmentation (8 cases), brownish globular nests (3 cases), bluish blackish fine dots (4 cases), Wickham's striae (2 cases) and pigmented targetoid globules (3 cases). In our study almost all the LPP cases had multiple dermoscopic patterns and combination of various signs mentioned above.

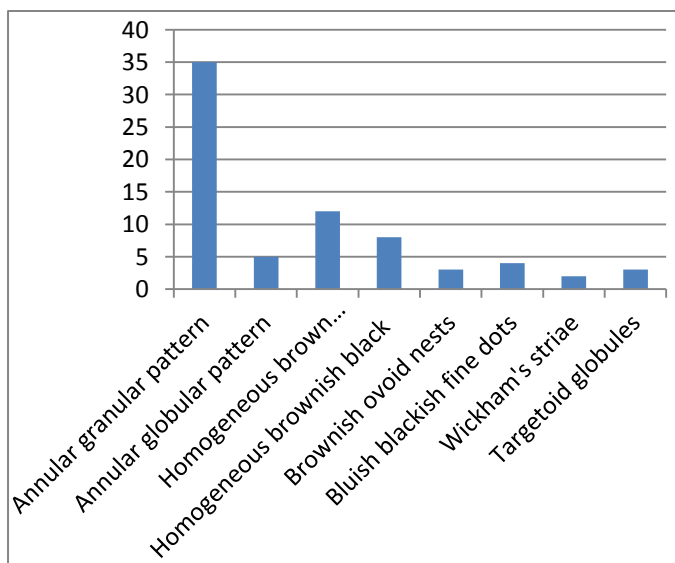


Figure 2: Various dermoscopic signs observed in our study

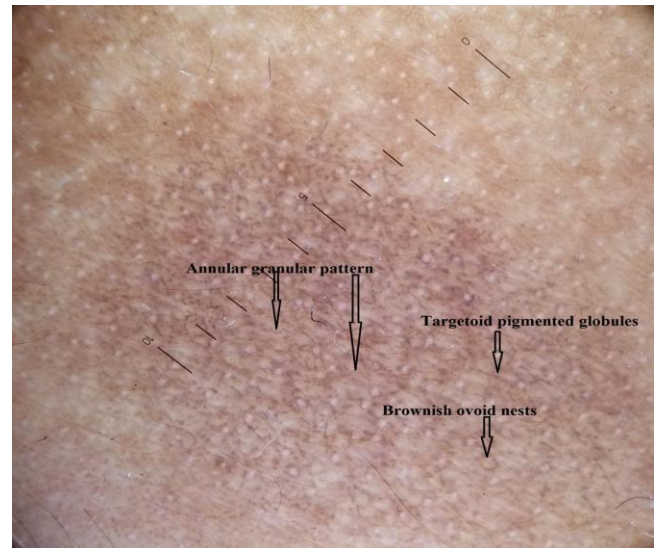

Figure 3: Dermoscopic picture of LPP lesion

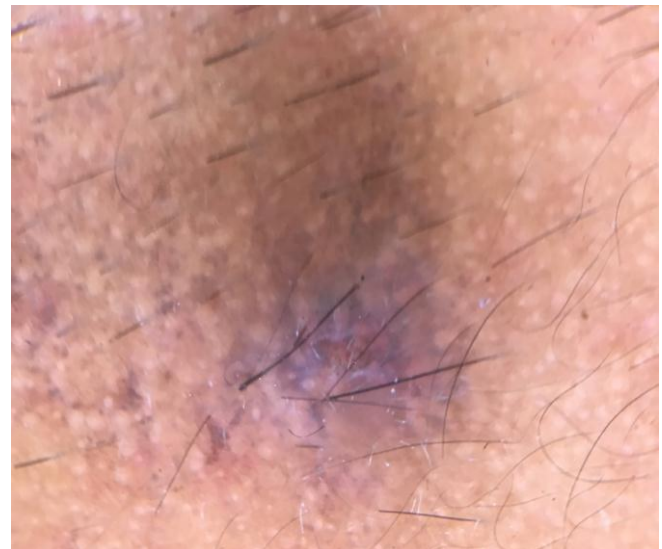

Figure 4: Rare occurrence of Wickham's striae with other dermoscopic findings in a case of LPP

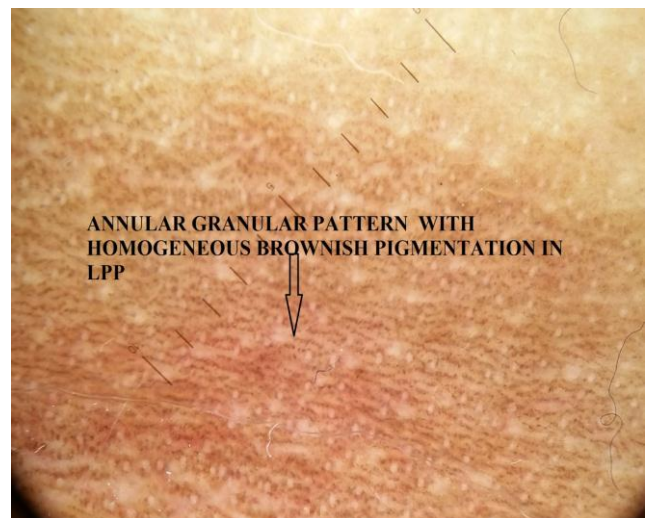


Figure 5: Classical annular granular pattern with background homogeneous brown pigmentation in a case of LPP

Discussion

Dermatoscope is an indispensable valuable bedside tool in clinical practice which allows us to make lucid and accurate diagnosis of LPP. It also helps to differentiate it from other causes of pigmentation. Our study showed that annular granular pattern is the commonest pattern in Indian LPP cases followed by homogeneous brown pigmentation. In our Indian LPP dermoscopy study we discovered three novel dermoscopic signs which includes brownish ovoid nests, pigmented targetoid globules and bluish blackish fine dots. In our study we got few unique cases where Wickham's striae was also present with other dermoscopic signs which supports the link of LPP to lichen planus. Dermatoscopic diagnosis of LPP is made by combination of various signs and should not be dependent on the presence of single marker. Other recent dermoscopic studies of LPP supported our findings.^[5-7]

References

- [1] Vega ME, Waxtein L, Arenas R, Hojyo T, Dominguez-Soto L. Ashy dermatosis versus lichen planus pigmentosus: A controversial matter. *Int J Dermatol* 1992; 31:87-8.
- [2] Kanwar AJ, Dogra S, Handa S, Parsad D, Radotra BD. A study of 124 Indian patients with lichen planus pigmentosus. *Clin Exp Dermatol* 2003; 28:481-5.
- [3] Al-Mutairi N, El-Khalawany M. Clinicopathological characteristics of lichen planus pigmentosus and its response to tacrolimus ointment: An open label, non-randomized, prospective study. *J Eur Acad Dermatol Venereol* 2010; 24:535-40.
- [4] Ghosh A, Coondoo A. Lichen Planus Pigmentosus: The Controversial Consensus. *Indian Journal of Dermatology*. September-October 2016; 61(5):482-486
- [5] Vázquez-López F, Vidal AM, Zalaudek I. Dermoscopic subpatterns of ashy dermatosis related to lichen planus. *Arch Dermatol*. 2010; 146(1):110.
- [6] Tan C, Min ZS, Xue Y, Zhu WY. Spectrum of dermoscopic patterns in lichen planus: a case series from China. *J Cutan Med Surg*. 2014; 18(1):28-32.
- [7] Lallas A, Kyrgidis A, Tzellos TG, et al. Accuracy of dermoscopic criteria for the diagnosis of psoriasis, dermatitis, lichen planus and pityriasis rosea. *Br J Dermatol*. 2012; 166(6):1198-205.